

6

*INJURY BIOMECHANICS RESEARCH
Proceedings of the Thirty-Second International Workshop*

Anterior Instrumentation of the Lumbar Vertebrae

P. Potier and G. Vallencien

This paper has not been screened for accuracy nor refereed by any body of scientific peers and should not be referenced in the open literature.

ABSTRACT

The need of data on the behaviour of the lumbar spine during the loading of the pelvis using an inflatable seat led to the necessity of the lumbar vertebrae to be instrumented. For the configuration of the test consisting of a seated human subject, the posterior instrumentation was not possible. Thus, the instrumentation technique applied consisted of the installation of boxes including the sensors (angular speed, accelerometers) on the anterior part of the vertebra body of L2, L3, and L5.

This paper deals with the following subjects: principle of the instrumentation of the lumbar spine, dissection and instrumentation of the vertebrae, checking of the position of the sensors boxes in comparison to the spine axes using X-rays, and 3D articulated arm recording of the initial position of the sensors when the subject is positioned.

In conclusion, the technique of instrumentation allowed measurement data to be acquired and curves characterizing the behaviour of the lumbar spine according to level of the instrumented vertebrae to be plotted.

INTRODUCTION

The need of data on the behaviour of the lumbar spine during the loading of the ischial tuberosity using an inflatable seat led to the schedule of cadaver tests.

The knowledge improvement that was expected concerned: the behaviour of the lumbar vertebrae and the sacrum, lumbar tolerance, injury mechanisms, and numerical model validation. Because of the seat back, the use of a posterior instrumentation was impossible. Consequently, a specially designed anterior instrumentation has been developed in order to provide pertinent data regarding the aim of the project.

Anatomical reminder. Facing an abdomen, from the front to the back, the main anatomical elements that are encountered are:

The front skin and the anterior muscles (Figure 1); behind which is the peritoneal cavity including the intestine, the stomach, the liver, the spleen, etc. (Figure 2); then, there is the retro-peritoneal area including the aorta, the inferior vena cava, the kidneys, etc. (Figure 3); next is our point of interest, the spine, particularly the five lumbar vertebrae (Figure 4); and lastly, there are the posterior muscles and the back skin.

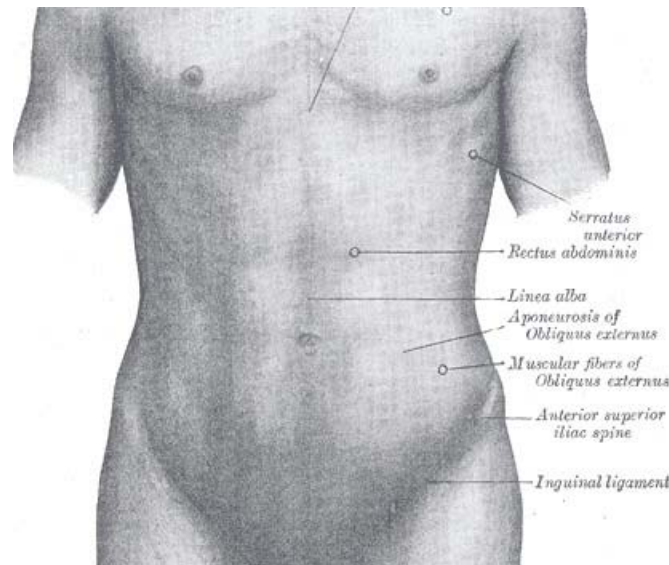


Figure 1: The front of the abdominal cavity, Gray anatomy.

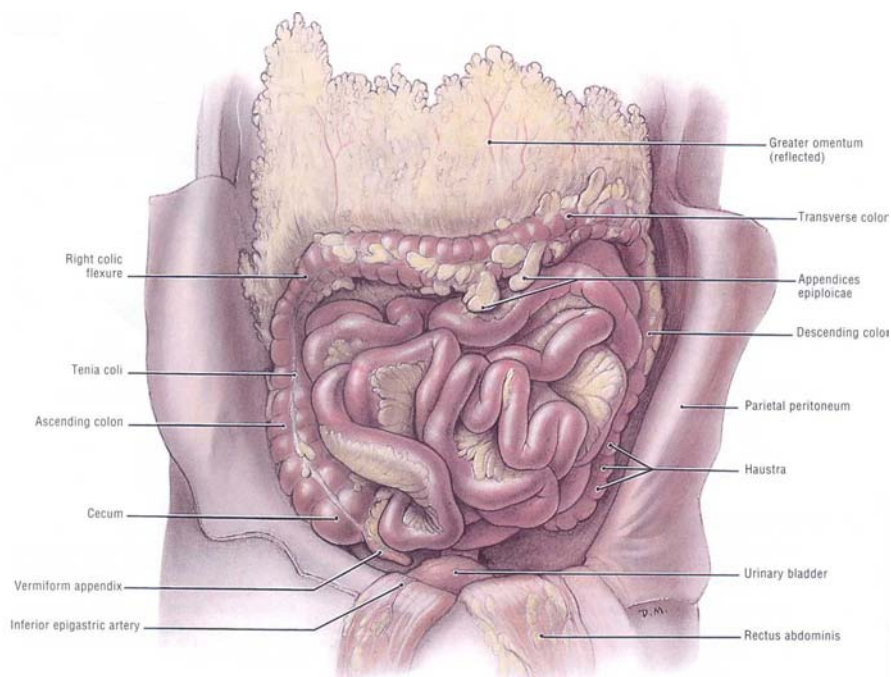


Figure 2: The peritoneal cavity, Grant anatomy.

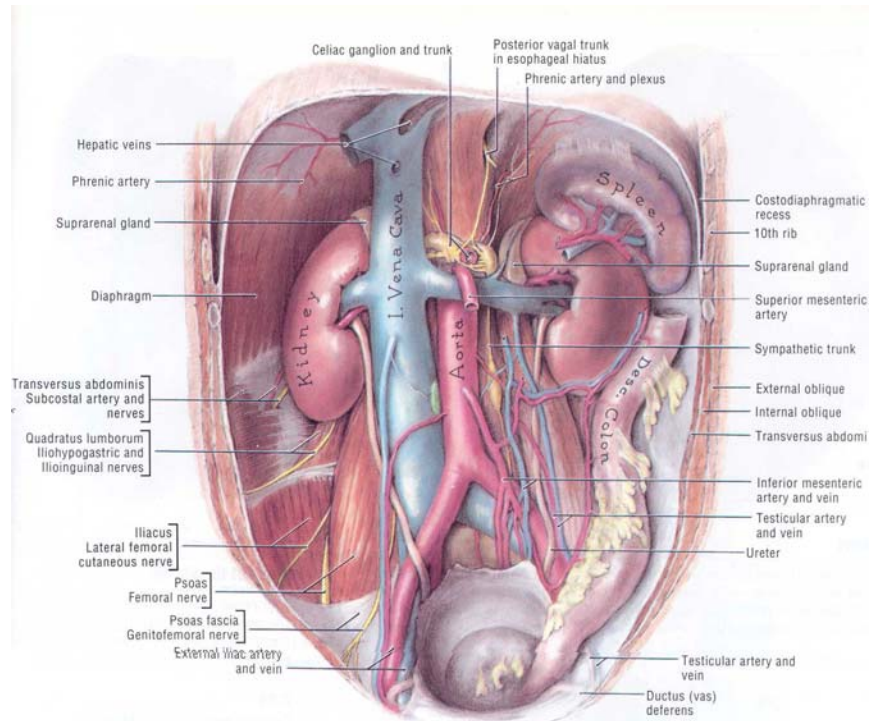


Figure 3: The retro-peritoneal cavity, Grant anatomy.

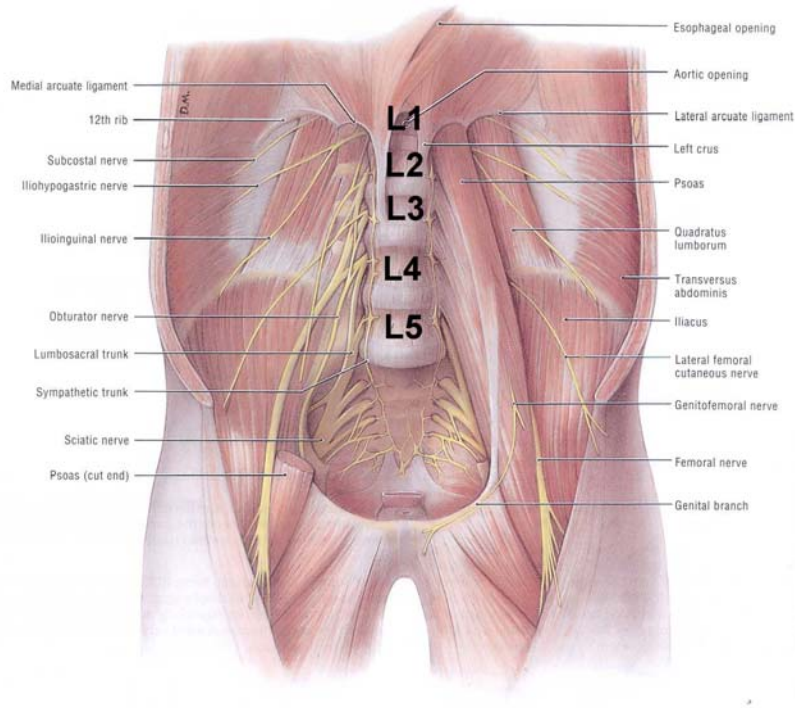


Figure 4: The five lumbar vertebrae, Grant anatomy.

The instrumentation must not induce injuries or changes of the position of the viscera. Consequently, to reach the retro-peritoneal area, the choice of a lateral incision was made.

METHODS

Principle

The principle of the instrumentation consists of the binding of sensors on the anterior wall of the vertebrae. The sensors are coupled with boxes that are screwed onto the vertebrae. The size of the sensors made it impossible to instrument each vertebra. The decision was made to instrument the second, third, and fifth lumbar vertebrae.

Presentation of the sensors. Each box is equipped with three linear accelerometers on the x , y , and z axes and one angular velocity sensor on the y axis, the aim being to acquire data on the behaviour of the lumbar spine in the x , z plane. The y axis accelerometer provides data on the occurrence of parasitic motion out of the x , z plane. When instrumenting, the sensors box is bound using 3 screws -- two screws on the front wall of the vertebra and one screw on the lateral wall of the vertebra. Each box is equipped with marks allowing the position to be recorded using a 3-D arm. (See Figures 5 and 6.)




Figure 5: Lateral view of the box.




Figure 6: Front view of the box.

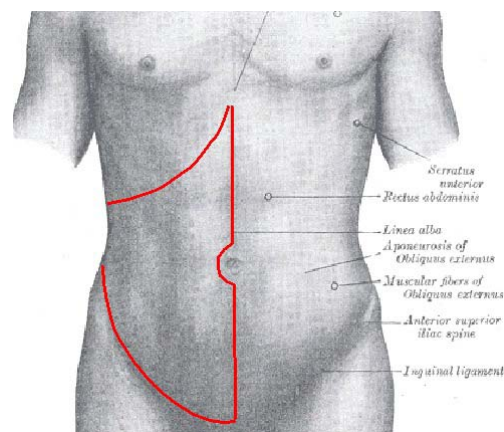


Figure 7: Drawing of the incision, Gray and Grant anatomy.

Dissection. The first step consists of the incision of the skin and the muscles, and the opening of the peritoneal cavity (Figure 7). The second step consists of a lateral incision in order to carry out a manual dissection at the rear of the ascending colon. The dissection is ended when the lumbar spine is reached (Figure 8). The third step consists of the dissection and ligation of the aorta and the vena cava.

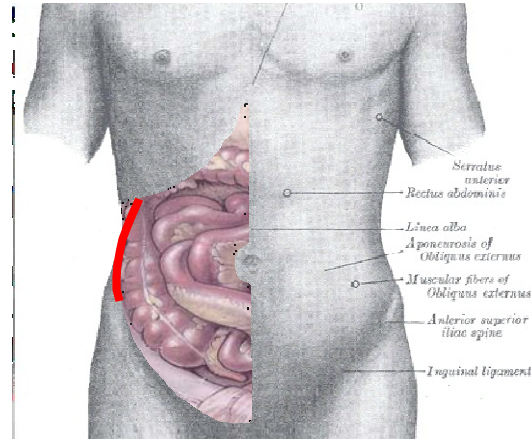


Figure 8: Drawing of the second incision, Gray and Grant anatomy.

Instrumentation

The instrumentation consists of the binding of three sensor boxes on the second, third, and fifth lumbar vertebrae. The alignment of the box on the y-axis of the vertebra must be respected in order to acquire the whole data on the behaviour of vertebra in the x, z plane. (See Figure 9.)

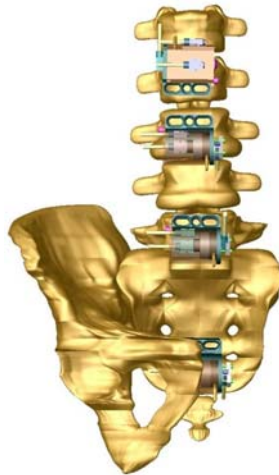

Figure 9: Drawing of the spine after the instrumentation.

The sacrum, in addition to L2, L3, and L5, is instrumented during the test. L2 is instrumented with the position of the box being reversed in order to prevent contact with the sensor box fixed on L3. L1 is not accessible enough to be instrumented. L4 is not instrumented because of the risk of contact with the sensor boxes fixed on L3 and L5.

In order to protect the angular velocity sensor from the biological liquids, the boxes are filled with thick grease. For the same reason, the accelerometers fixed outside the box, are also protected with grease.

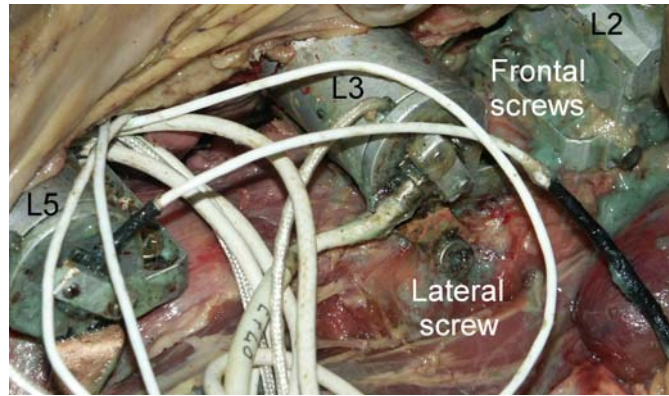


Figure 10: Sensors boxes fixed on the vertebrae using three screws.

The checking of the instrumentation is carried out using X-ray. The y-axis of the sensor has to correspond to the y-axis of the vertebra (Figure 11). When the instrumentation is complete, the PMHS is installed on the test seat and positioned. Then the retro-peritoneal area is lit for the marks on the boxes to be visible. The position of the sensors is recorded using a 3D arm (Figure 12). Finally, the abdominal wall is sutured, taking care that no change of position occurs. Performance of the test could then be carried out.

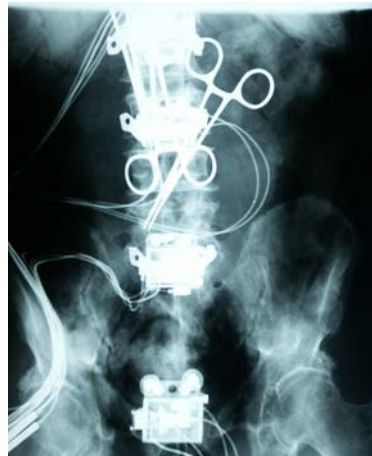

Figure 11: Checking of the position of the sensors boxes.

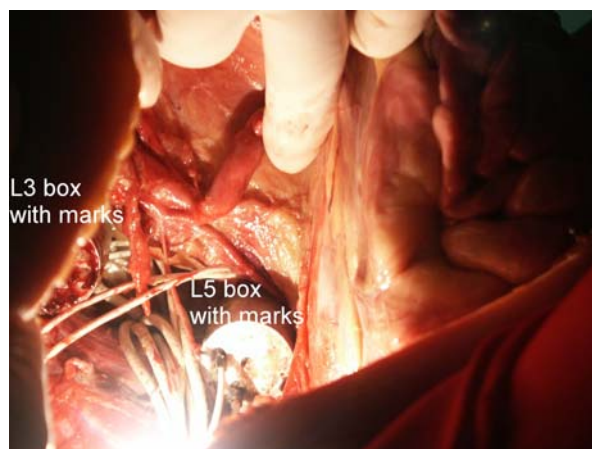


Figure 12: Lighted retro-peritoneal area during the use of the 3D arm.



Figure 13: Out-of-Position PMHS.

The test illustrated in Figure 13 consisted of an Out-of-Position passenger, with the ischial tuberosity positioned above the seat bag in order to obtain the most pejorative configuration for the lumbar spine. When an autopsy is carried out after a test, the instrumentation is checked and the position of the vertebrae in comparison with the sensor boxes is recorded using a 3D arm (Figure 14).

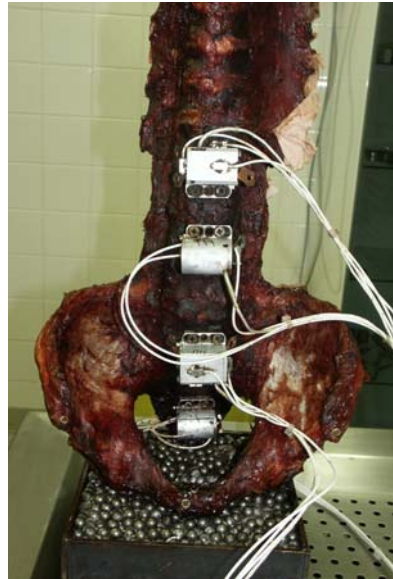

Figure 14: Checking of the alignment of the sensors boxes.

RESULTS

The first results on the behavior of the lumbar spine are provided by three graphs (Figures 15, 16, and 17). The comparison of the angular velocity of the vertebrae (Figure 15) shows that the closer the vertebrae is to the loading, the earlier the rotation begins. The L4 curve is an average of L3 and L5, and is homogenous compared to the other measurement. The comparison of the rotation (in degrees) of the vertebrae (Figure 16) shows that, at 140ms, all the rotations are equal. Later, the initial flexion motion of the lumbar spine becomes an extension motion. The comparison of the inter-vertebral rotation (Figure 17) shows that the rotations are identical, except L5/S1 that is 68% higher.

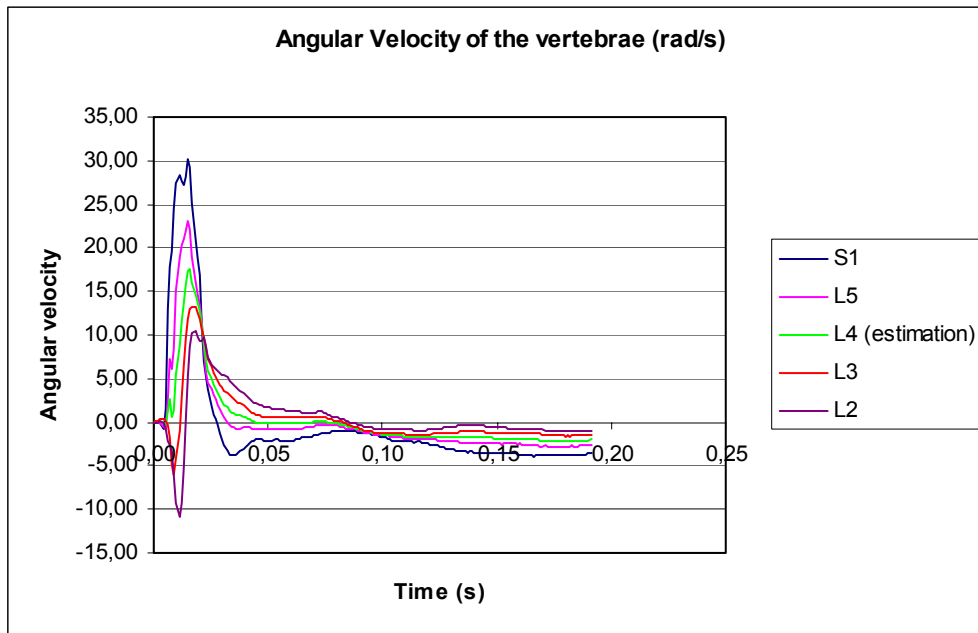


Figure 15: Comparison of the angular velocity of the vertebrae.

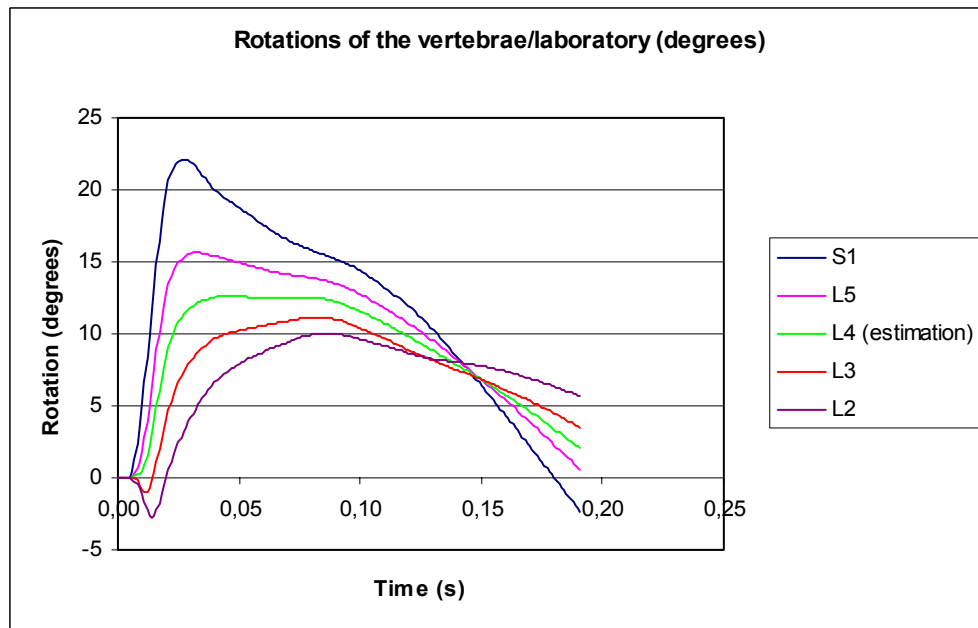


Figure 16: Comparison of rotation of the vertebrae.

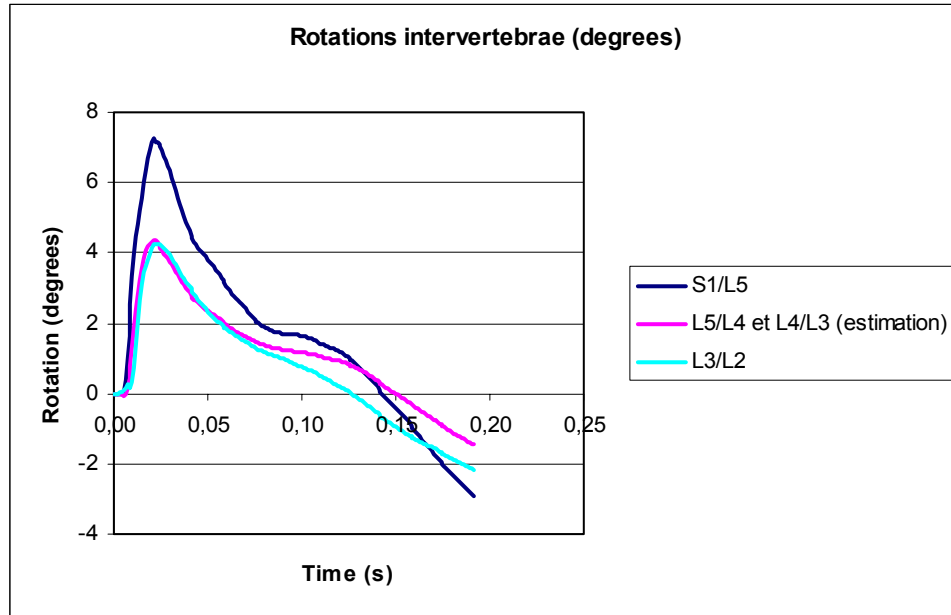


Figure 17: Comparison of the inter-vertebral rotation.

CONCLUSION

The checking of the instrumentation during the autopsy and the data acquired during the tests show that the methodology described above is feasible and capable to provide pertinent data. However, some difficulties are met. In particular, it takes a long time to carry out the instrumentation and the acquisition of the position of the sensors using the 3D arm.

The care that must be taken during the acquisition of the position of the sensors in order to keep the PMHS in position imposes the application of the following sequence:

- The acquisition of the initial position of the PMHS using external anatomical points;
- The acquisition of the position of the sensor boxes using the 3D arm;
- The checking that no change of the position occurred, using the 3D arm;
- The suture of the abdominal wall;
- The checking that no change of the position occurred.

If any change of the position occurred, the procedure has to be re-initialized.

The limits of the methodology

The instrumentation of L1 is impossible because of its too high position. The instrumentation of each lumbar vertebra is impossible because of the risk of contact between the boxes during the test.

Special cares

Generally, the spine is not perfectly straight when the PMHS is lying on its back. Consequently, it is necessary to take special care to obtain specific alignment on the vertebra without being influenced by the curvature of the spine when screwing the boxes.

The last point concerns the biological liquid isolation. This action is necessary in order to prevent data from being lost. It seems that the use of thick grease for the filling of the boxes and the isolation of the outside accelerometers is a good solution.

ACKNOWLEDGEMENTS

The authors wish to thank Xavier Trosseille from L.A.B. Renault-PSA, Peugeot-Citroen and Pascal Baudrit, CEESAR for their support.

DISCUSSION

PAPER: **Anterior Instrumentation of the Lumbar Vertebrae**

PRESENTER: ***Pascal Potier, Experimental Pathology Laboratory and Biomechanical Experimentation Department, CEESAR of France***

QUESTION: *Guy Nusholtz, DaimlerChrysler*

The position that you chose looks more like the result of a really bad day of work and coming home and relaxing. Why did you choose that? It doesn't look like a typical automotive driving position. Why was that?

ANSWER: You mean that it's an out of position? It's not standard position?

Q: Yeah. It's not a standard. So the reason you choose it is you think that would be the typical out-of-position?

A: To have a loading of the spine due to resistance with the cushion or rather due to the interaction of the inflatable seat with the ischial tuberosity.

Q: Okay. So as I understand your answer, it's to exaggerate the problem.

A: Yeah. To maximize loading of the spine in order to induce injuries.

Q: Okay. So it wasn't a typical driving position?

A: No, no, no.

Q: Okay.

A: It's out-of-position.

Q: Second—Second question is: You've got a lot of instrumentation there. Do you think that might affect the response or do you think that might not?

A: A modification of the behavior?

Q: Yeah.

A: And the data? So, that is the question? The first generation of sensors boxes have a weight about 40 grams and the second generation, about 100 grams. It's because of the weight of the ATA. The ATA 200 radians per second is very, more heavy than the first generation. So, we have the question of the modification of the behavior of the spine because of the instrumentation. I hope that, even if there is modification, it's not too much important. And then, I think that, in spite of the difference of weight between the boxes, the curves seem to be logical or coherent.

Q: Okay.

QUESTION: *Srini Sundararajan, Ford Motor Company*

Couple of questions: One is, when you instrumented it, did you check the condition of the ALL or the ligaments? Did you have to cut through the ligaments when you put the angular velocity sensor on it?

ANSWER: You talk about the ligaments?

Q: Yes.

A: There is just a dissection of the aorta and vena cava in order to separate these vessels from the spine and just have more space to install the instrumentation. These vessels are not removed; they are just ligatured and cut. The only intrusion in the spine consists of the three screws in the vertebral wall. That's all.

Q: Okay. Did you do just only one test or have you used this pattern for the other tests also? How many cadavers did you test?

A: Six tests were carried out.

Q: And when you do the autopsy after the test, what was the condition of the vertebrae and the disks and the ligaments?

A: It was okay.

Q: Okay. Thank you.